

THE EFFECTIVENESS OF GUAVA
(*Psidium guajava*) AND
SENDUDUK LEAVES (*Melastoma
malabathricum* L.) EXTRACT
GEL TOWARDS THE
INFLAMMATION MARKERS AND
COLLAGENS ON INDUCED
MALE RATS (SPRAGUE DAWLEY)

Submission date: 14-May-2022 09:52AM (UTC-0400)

Submission ID: 1836139040

File name: THE_EFFECTIVENESS_OF_GUAVA_AND_SENDUDUK_LEAVES_EXTRACT_GEL.docx (562.2K)

Word count: 3155

Character count: 18096

WITH DIAB

by Tonny Cortis Maigoda

THE EFFECTIVENESS OF GUAVA (*Psidium guajava*) AND SENDUDUK LEAVES (*Melastoma malabathricum* L.) EXTRACT GEL TOWARDS THE INFLAMMATION MARKERS AND COLLAGENS ON INDUCED MALE RATS (SPRAGUE DAWLEY) WITH DIABETES

TONNY CORTIS MAIGODA^{1*}, REFDANITA² and IDRAMSYAH³

¹Department of Nutrition, Poltekkes Kemenkes Bengkulu, 38225 Bengkulu, Indonesia

²Faculty of Pharmacy, Institute of Science and Technology National, South Jakarta, 32640, Jakarta, Indonesia

³Department of Nursing, Poltekkes Kemenkes Bengkulu, 38225 Bengkulu, Indonesia

*E-mail: tony@poltekkesbengkulu.ac.id

Accepted 3 March 2022, Published online 31 March 2022

ABSTRACT

This study aimed to measure the effectiveness of a mixed extract gel from *Melastoma malabathricum* L. (ML) and *Psidium guajava* leave (PG) on inflammatory markers and collagen distribution wound tissue in rats (Sprague Dawley) induced with diabetes. This was an experimental study with a randomized block design to 20 male rats divided into 4 treatment groups. Group 1 is negative control (gel blank). Group 2 is positive control (clindamycin gel), Group 3 used 4% formula mixture of ML + PG leaves, and Group 4 used 6% gel form a mixture of ML + PG leaves extract the gel. The results showed that there was a significant difference ($p < 0.001$) in total Tumor Necrosis Factor-alpha (TNF- α) treated with 6% extract gel (ML + PG) from a level of 25.0 pg/mL on the 2nd day to 1.68 pg/mL on the 6th day. The smallest wound diameter was 0.75 mm² as observed on the 6th day in rats treated with 6% extract gel (ML + PG). The largest distribution of collagen area was 219,8 (86,2%) treated by 6% extract gel (ML + PG).

Key words: Collagen, diabetic rats, extract gel, TNF- α , wound diameter

INTRODUCTION

The increased prevalence of Diabetes Mellitus (DM) leads to the development of various DM complications. One complication is diabetic neuropathy and chronic vascular disorders that would have an advanced impact in complications of diabetic foot (Waspadji, 2014). According to the International Diabetes Federation (IDF), people with diabetes have 25 times the risk of experiencing amputation than normal people (International Diabetes Federation, 2013). Approximately 1-7% of DM patients experience amputation due to diabetic ulcers (Kong & Chan, 2015). According to Geiss *et al.* (2018) the resurgence of diabetes-related nontraumatic lower-extremity amputation in the young and middle-aged adult US population.

The experts used to argue that the concept of wound care was sterile, dry, and open. Wound healing and bacterial infections are best prevented if wounds are left open and dry. As a result, most of the wounds are wrapped in cotton or gauze so that the wound is dry. However, in 1962 the results of G.D Winter's research, published in Nature, on the optimal

environmental conditions for wound healing became the basis for knowing the concept of "Moist Wound Healing". This method is used to maintain wound moisture by using moisture-holding dressings, so that wound healing and tissue growth can occur naturally. The emergence of the concept of "Moist Wound Healing" accompanied by supporting technology, has become the basis for the emergence of modern wound dressings (Souliotis *et al.* 2016).

The initial phase of wound healing is the inflammatory phase. If the inflammatory phase is not treated effectively, it takes longer for the wound to progress to the subsequent wound healing phase. As a result, it can lead to amputation and even death. Natural Compound is an alternative way to cure wound healing that is relatively safe and has minimal side effects compared with chemical medication. Therefore, efforts to develop natural ingredients in the management of diabetic wound complications are needed.

The development of natural ingredients still focuses on the concept of moisture in modern wound care. *Psidium guajava* and *Melastoma malabathricum* L. leaves have medicinal properties and are beneficial for health. Both of these leaves are often used to treat diabetic wounds as traditional medicine. A study

* To whom correspondence should be addressed.

has shown that the mixed extracts of *Melastoma malabathricum* L. and *Psidium guajava* leaves had the potential to heal wounds significantly ($p < 0.001$) by reducing the wide parameter of diabetic foot wounds in rats compared to other groups (Maigoda *et al.*, 2019). Nonetheless, data remain unknown related to inflammatory markers and collagen formation.

Therefore, this study was conducted to determine the effect of *Psidium guajava* and *Melastoma malabathricum* L. leaves extract gels on inflammatory markers and collagen formation in diabetic wounds in rats.

The use of the gel in a combination of *Psidium guajava* and *Melastoma malabathricum* L. leaves extract is easier and more practical, and the role of phytochemicals inside the gel can provide an optimal moist atmosphere for a long time on the wound surface compared to pure extracts. The moist atmosphere in the wound can make phytochemical substances create healthy cells and growth factors work optimally. The study is critical as the pre-clinical trial is required before testing the developed products in patients with diabetes.

MATERIALS AND METHODS

The research method was experimental with a randomized group design (randomized group design). The randomized block design was divided into four treatments, that are: negative control (gel blank), positive control (clindamycin gel), 4% gel formula *Melastoma malabathricum* L. (ML) and *Psidium guajava* Leaf (PG), and 6% gel (ML + PG). *In-vivo* method analysis was used for six days of intervention using *Psidium guajava* and *Melastoma malabathricum* L. leaves obtained from the city of Bengkulu in 2019.

Extract preparation

The extraction process was made using the maceration method of 70% ethanol solvent. *Psidium guajava* and *Melastoma malabathricum* L. leaves as much as 500 g each were washed thoroughly, the leaf size was reduced (chopped) to form small pieces of leaves and put into 5 L of ethanol. The mixture was stirred several times for 3 days. Every day, the filtrate is filtered, and a new solvent is replaced after 24 h. After the filtration process, the filtrate was dried in a rotary vacuum evaporator (temperature at 50 °C, rotation at 80/min) and evaporated to obtain a dry/thick extract with constant weight using a water bath. Then stored, and made into a gel.

Experimental animals

Twenty Healthy Male Rats (Sprague Dawley) have been obtained from PT. PTM (Badan Pengawas Obat dan Makanan) Jakarta, 8 weeks old and weighing 250-270 grams.

Diabetes induction procedure

A total of 20 Sprague Dawley (SD) rats were induced by injection of Alloxan Monohydrate dissolved in saline solution with a single dose of 120 mg/kg body weight (BW) intraperitoneally (abdominal cavity). The success of diabetes condition is measured if on the fifth day (120 h) fasting blood glucose in preprandial >200 mg/dL or when blood sugar levels >300 mg/dL. Blood sampling was done through the tail vein (Middha *et al.* 2019).

Wound creation and tissue collection

The rats were anesthetized using a combination of ketamine (100 mg/kg) and xylazine (5 mg/kg) intramuscularly to relieve pain before the injury. The rats' dorsal hair was shaved until the skin was exposed. The skin was then cleaned using 70% ethanol. A rectangle was marked on the foot's dorsal surface using a tape measure, and then a layer of skin at total thickness with a wound diameter of 5 mm was peeled off under pressure using a biopsy punch (Kai Industrial Co., Ltd., Gifu, Japan) under sterile conditions. The wound was covered with a polyurethane film and an elastic adhesive bandage. At some point in time, a sample of rat blood was taken from the orbital vein to measure cytokine concentrations, and the tissue was used for histological analysis.

Measurement of cytokine concentration

The sample of rat blood serum homogenized in Phosphat-Buffer Saline (PBS) and the TNF- α concentration in the supernatant was measured using the enzyme-linked immunosorbent assay (ELISA) kit Rats (Legend Max, Biolegend, San Diego CA). The results are presented as the mean value of each treatment.

Histological analysis

Morphometric analysis was performed using digital images. Collagen identification was made using Hematoxylin & Eosin (H&E) and Masson's trichrome staining on the cross-section for analysis by fluorescence microscopy using a 20x magnification and software capture system AxioVision 4.7.2.0 v (Carl Zeiss, Germany). The images were processed using Image J 1.49 software, 64-bit version (National Institutes of Health, Bethesda, USA) using the RGB (Red, Green, Blue) method, using three-color distributions (Acevedo *et al.* 2010).

Statistical analysis

The data was presented in mean + standard deviation (SD), statistical analysis between treatment groups used analysis of variance (ANOVA), advanced test using Duncan's test, p -value < 0.05 .

RESULTS AND DISCUSSION

Blood TNF- α production

The researchers measured the TNF- α concentration in homogenized supernatant from blood samples that had been collected at time intervals of the second and sixth days. TNF- α has increased since the injury. Compared with the control, there was a significant reduction in injuries after the sixth day in the control group and the 4% ML + PG gel group and 6% ML + PG gel group (Figure 1).

In another study using a similar animal model, the administration of flavonoid gel extract from cassava leaves to rats with periodontitis reduced the expression of TNF- α at a concentration of 50%. The use of a gel application containing flavonoids from garlic extract (garlic) also significantly reduced TNF- α levels in rats with tumors and thrush (Anggraeni *et al.* 2020). Administration of flavonoids in the form of quercetin has been shown to inhibit the production of proinflammatory cytokine TNF- α by modulating Nuclear Factor Kappa B Subunit 1 (NF- κ B) (Leyva-López, *et al.* 2016).

Histological assessment and wound healing

Wound healing was measured by using an experimental animal model, wounds were made on the back of the rats with full-thickness, and the wound condition was observed at certain time intervals. Macroscopically, the wound shows improvement over time. The wound was covered up to 80% on day 3, and by day 10 the wound was closed entirely, the highest percentage of wound improvement was 93.6 % treated by 6% ML + PG gel comparing other groups. The collagen formation was measured by using Image J 1.49 software, 64-bit version (National Institutes of Health, Bethesda, USA) (Acevedo *et al.* 2016) (Figure 2).

Wound healing is an essential but sophisticated process in humans or animals, containing a multifaceted process governed by sequential yet overlapping phases, such as hemostasis/ inflammation phase, proliferation phase, and remodeling phase (Lindley *et al.* 2016).

Fibroblasts play an essential role in wound closure in the skin, from the beginning of the inflammatory phase to forming the extracellular matrix, which is very important as a barrier against potential infection in wounds (Landén *et al.* 2016). Plant components that can have the effect of treating wounds such as flavonoids, saponins, phenols, tannins, and essential oils are known to have properties as antiseptic, anti-inflammatory, antioxidant, stimulating collagen

synthesis, triggering cell proliferation activity, and various other biological activities that have wound-healing effects (Bahramsoltani *et al.* 2014). The significant decrease in TNF- α levels on the sixth day in the positive control group, 4% ML + PG gel group, and 6% ML + PG gel group compared to the control group showed the active component's role in inflammatory conditions. In histological measurements, there was also a significant increase in collagen formation in the ML + PG 4% treatment group and the 6% ML + PG gel group with a higher percentage of collagen area compared to the negative control group even when compared to the clindamycin positive group.

Several theories have explained the relationship between anti-inflammatory activity with flavonoids and their structure (Chanput *et al.*, 2016). The presence of hydroxyl groups in the C-5, C-7 chains in ring A, and 11'-4 in ring-B in the flavonoid structure plays a vital role in the significant inhibition of TNF- α production (Chanput *et al.* 2016). Administration of topical drugs that contain flavonoid components such as myricetin as in a recent report by Elshamy *et al.* (2020) and also from publications of topical drug administration containing 5,7,3,3', 4'-pentahydroxyl flavonoids that support wound repair by increasing wound formation collagen matrix and modulates cytokine levels (Gopalakrishnan *et al.*, 2016).

Melastoma malabathricum L. and *Psidium guajava* leaf contain a rich amount of flavonoids, alkaloids, tannins, saponins, quinones, steroids, and triterpenoids (Maigoda *et al.* 2019). These substances contain active components of antioxidants, which the mixed extracts lead to significant improvement in wound healing (Bhangale, Charya 2014; Durkar *et al.* 2014; Bouaziz-Ketata *et al.*, 2015; Mamta *et al.*, 2015; Bhatt & Patel 2015; Chandr *et al.* 2015). Ulcer wounds on rats' feet were better when compared to other treatment groups (Maigoda *et al.*, 2019).

The improvement of cytokines including TNF- α and growth factors manipulate the inflammatory phase of healing. Inflammation is followed by the proliferation of fibroblasts, which lay down the extracellular matrix; however, cytokine levels are higher in nonhealing wounds especially the levels of IL-1, IL-6, and TNF- α (Mohd. Yussof *et al.*, 2012).

In this study, some beneficial effects of combination gel extract *Melastoma malabathricum* L. (ML) and *Psidium guajava* Leaf (PG) can reduce inflammation markers, wound healing improvement, and collagen formation in rats. Therefore, it could be continued to apply for humans as a nutraceutical innovation product.

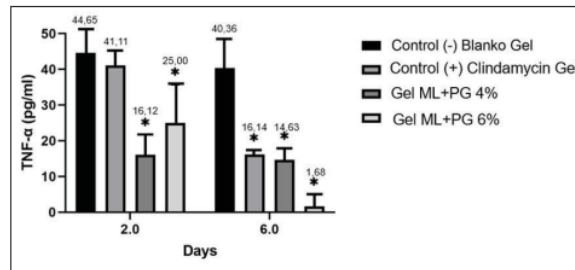


Fig.1. The serum concentration of TNF- α . TNF- α was measured on the second and sixth days after wound making. Each column represents the median + SD of each of the four wounds of the four mice per treatment group, * $P < 0.05$.

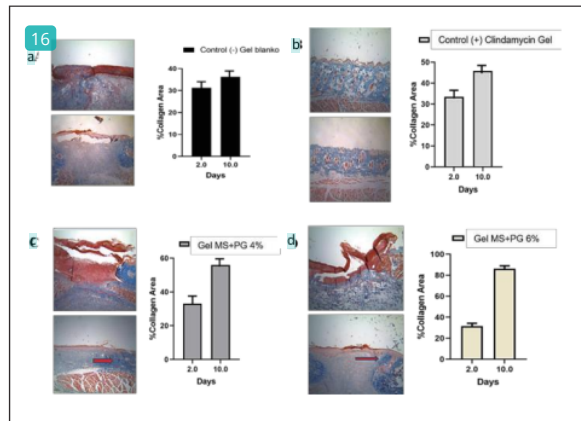


Fig. 2. The effect of treatment on rat wound healing in the form of histopathological comparison of skin tissue and the percent area of collagen which we treated with gel blank (a), clindamycin gel (b), 4% ML + PG (c) gel, and 6% ML + PG gel treatment (d) on the 2nd and 10th day after wound making. Each column depicts the median + SD of each of the four wounds of four rats per treatment group. The top image showed the histopathological image of the rat's skin after two days of treatment, and the bottom image shows the histopathological image of the rats' skin after ten days of treatment.

CONCLUSION

This study concluded that TNF- α plays an essential role in the initial biomarker inflammation of wound healing in diabetic rats with topical gel combination between *Melastoma malabathricum* L. (ML) and *Psidium guajava* (PG) leaves that are given as much as 4% and 6% to have a beneficial effect on wound healing. The largest impact of collagen formation was seen in rats treated with 6% gel (ML + PG).

ACKNOWLEDGMENTS

The authors would like to acknowledge the financial support for implementing this study from DIPA (Financial Project of research) in Poltekkes Kemenkes Bengkulu.

ETHICAL STATEMENT

All protocols described in the study were accepted by the animal research ethics committee of Universitas Pembangunan Nasional Veteran (UPN Veteran) Jakarta with ethic number: B/2210/X/2019/KEPK.

CONFLICT OF INTEREST

The authors declare no conflict of interest.

REFERENCES

- Acevedo, C.A., López, D.A., Tapia, M.J., Enrione, J., Skurtyts, O., Pedreschi, F., Brown, D.L., Creixell, W. & Osorio, F. 2010. Using RGB image processing for designing an alginate edible film. *Food and Bioprocess Technology*, 5: 1511–1520. <https://doi.org/10.1007/s11947-010-0453-y>

- Kong, A.P.S. & Chan, J.C.N. 2015. Hypoglycemia and comorbidities in type 2 diabetes. *Current Diabetes Reports*, **15**: 80. <https://doi.org/10.1007/s11892-015-0646-x>
- Anggraeni, D., Kamaluddin, K. & Theodorus, T. 2020. Effectiveness of garlic water extract gel (*Allium sativum*. L) against Necrotic Factor Alpha (TNF- α) tumors and mouth ulcer diameter in rats. *Biomedical Journal of Indonesia*, **6(1)**: 27-34. <https://doi.org/10.32539/bji.v6i1.7970>
- Bahramsoltani, R., Farzaei, M.H. & Rahimi, R. 2014. Medicinal plants and their natural components as future drugs for the treatment of burn wounds: An integrative review. *Archives of Dermatological Research*, **306(7)**: 601-617. <https://doi.org/10.1007/s00403-014-1474-6>
- Bhangale, J. & Acharya, S. 2014. Antiarthritic activity of *Cynodon dactylon* (L.) Pers. *Indian Journal of Experimental Biology*, **2(3)**: 215-222.
- Bhatt, A. & Patel, V. 2015. Antioxidant potential of banana: Study using simulated gastrointestinal model and conventional extraction. *Indian Journal of Experimental Biology*, **53(2015)**: 457.
- Bouaziz-Ketata, H., Zouari, N., Salah, H.B., Rafrafi, M. & Zeghal, N. 2015. Flavonoid profile and antioxidant activities of methanolic extract of *Hyparrhenia hirta* (L.) Stapf. *Indian Journal of Experimental Biology*, **53(4)**: 208-215.
- Chandra, A.K., Mondal, C., Sinha, S., Chakraborty, A. & Pearce, E.N. 2015. Synergic actions of polyphenols and cyanogens of peanut seed coat (*Arachis hypogaea*) on cytological, biochemical and functional changes in thyroid. *Indian Journal of Experimental Biology*, **53(3)**: 143-151.
- Chanput, W., Krueyos, N. & Ritthiruangdej, P. 2016. Anti-oxidative assays as markers for anti-inflammatory activity of flavonoids. *International Immunopharmacology*, **40(2016)**: 170-175. <https://doi.org/10.1016/j.intimp.2016.08.038>
- Durkar, A.M., Patil, R.R. & Naik, S.R. 2014. Hypolipidemic and antioxidant activity of ethanolic extract of *Symplocos racemosa* Roxb. in Hyperlipidemic rats: An evidence of participation of oxidative stress in hyperlipidemia. *Indian Journal of Experimental Biology*, **52(1)**: 36-45.
- Elshamy, A.I., Ammar, N.M., Hassan, H.A., El-Kashak, W.A., Al-Rejaie, S.S., Abd-ElGawad, A.M. & Farrag, A.-R.H. 2020. Topical wound healing activity of myricetin isolated from *Tecomaria capensis* v. *aurea*. *Molecules*, **25(21)**: 4870. <https://doi.org/10.3390/molecules25214870>
- Geiss, L.S., Li, Y., Hora, I., Albright, A., Rolka, D. & Gregg, E.W. 2019. Resurgence of diabetes-related nontraumatic lower-extremity amputation in the young and middle-aged adult U.S. population. *Diabetes Care*, **42(1)**: 50-54. <https://doi.org/10.2337/dc18-1380>
- Gopalakrishnan, A., Ram, M., Kumawat, S., Tandan, S. & Kumar, D. 2016. Quercetin accelerated cutaneous wound healing in rats by increasing levels of VEGF and TGF- β 1. *Indian Journal of Experimental Biology*, **54(3)**: 187-195.
- International Diabetes Federation. 2013. Atlas Diabetes. URL [www.idf.org/diabetesatlas]. <https://diabetesatlas.org/> (accessed 16.11.2021).
- Landén, N.X., Li, D. & Stähle, M. 2016. Transition from inflammation to proliferation: A critical step during wound healing. *Cellular and Molecular Life Sciences*, **73(20)**: 3861-3885. <https://doi.org/10.1007/s00018-016-2268-0>
- Lindley, L.E., Stojadinovic, O., Pastar, I. & Tomic-Canic, M. 2016. Biology and biomarkers for wound healing. *Plastic and Reconstructive Surgery*, **138(3)**: 185-285. <https://doi.org/10.1097/PRS.0000000000002682>
- Maigoda, T.C., Siregar, A., Podojoyo, Ridhowati, S. & Krisnasary, A. 2019. Wound healing and blood sugar effect of *Psidium guajava* L. leaves and *Melastoma malabathricum* L. leaves on rats with diabetic foot ulcer. *Journal of Applied Sciences*, **19(4)**: 287-294. <https://doi.org/10.3923/jas.2019.287.294>
- Mamta, Mehrotra, S., Amitabh, Kirar, V., Vats, P., Nandi, S.P., Negi, P.S. & Misra, K. 2015. Phytochemical and antimicrobial activities of himalayan *Cordyceps sinensis* (Berk.) Sacc. *Indian Journal of Experimental Biology*, **53(1)**: 36-43
- Middha, S.K., Usha, T., Basistha, B.C. & Goyal, A.K. 2019. Amelioration of antioxidant potential, toxicity, and antihyperglycemic activity of *Hippophae salicifolia* D. Don leaf extracts in alloxan-induced diabetic rats. *3 Biotech*, **9**: 308. <https://doi.org/10.1007/s13205-019-1840-3>
- Mohd. Yussof, S.J., Omar, E., Pai, D.R. & Sood, S. 2012. Cellular events and biomarkers of wound healing. *Indian Journal of Plastic Surgery*, **45(2)**: 220-228. <https://doi.org/10.4103/0970-0358.101282>
- Leyva-López, N., Gutierrez-Grijalva, E.P., Ambriz-Perez, D.L. & Heredia, J.B. Flavonoids as cytokine modulators: A possible therapy for inflammation-related diseases. *International Journal of Molecular Sciences*, **17(6)**: 921. <https://doi.org/10.3390/ijms17060921>
- Souliotis, K., Kalemikerakis, I., Saridi, M., Papageorgiou, M. & Kalokerinou, A. 2016. A cost and clinical effectiveness analysis among Moist wound healing dressings versus traditional methods in home care patients with pressure ulcers. *Wound Repair and Regeneration*, **24(1)**:

596-601. <https://doi.org/10.1111/wrr.12433>
Waspadji, S. 2014. Komplikasi kronik diabetes:
Mkanisme terjadinya, diagnosis, dan strategi
pengelolaan. In: *Buku Ajar Ilmu Penyakit*

Dalam. S. Setiati, I. Alwi, A.W. Sudoyo, M.
Simadibrata, B. Setiyohadi and A.F. Syam.
6th Ed. Pusat Penerbitan Ilmu Penyakit Dalam
FKUI: 2359, Jakarta.

THE EFFECTIVENESS OF GUAVA (*Psidium guajava*) AND SENDUDUK LEAVES (*Melastoma malabathricum* L.) EXTRACT GEL TOWARDS THE INFLAMMATION MARKERS AND COLLAGENS ON INDUCED MALE RATS (SPRAGUE DAWLEY) WITH DIAB

ORIGINALITY REPORT

24%

SIMILARITY INDEX

19%

INTERNET SOURCES

20%

PUBLICATIONS

5%

STUDENT PAPERS

PRIMARY SOURCES

1 oamjms.eu Internet Source 4%

2 mail.scialert.net Internet Source 3%

3 José Carlos Tatmatsu-Rocha, Carla Roberta Tim, Lucimar Avo, Rubens Bernardes-Filho et al. "Mitochondrial dynamics (fission and fusion) and collagen production in a rat model of diabetic wound healing treated by photobiomodulation: comparison of 904 nm laser and 850 nm light-emitting diode (LED)", *Journal of Photochemistry and Photobiology B: Biology*, 2018
Publication 2%

4 www.pstu.ac.bd Internet Source 2%

| | | |
|----|---|-----|
| 5 | Internet Source | 1 % |
| 6 | Peng-Hui Wang, Ben-Shian Huang, Huann-Cheng Horng, Chang-Ching Yeh, Yi-Jen Chen. "Wound healing", Journal of the Chinese Medical Association, 2018 Publication | 1 % |
| 7 | juniperpublishers.com Internet Source | 1 % |
| 8 | www.mdpi.com Internet Source | 1 % |
| 9 | Submitted to Augusta State University Student Paper | 1 % |
| 10 | Tonny Cortis Maigoda, Afriyana Siregar, Podojoyo ., Sherly Ridhowati, Arie Krisnasary. "Wound Healing and Blood Sugar Effect of Psidium guajava L. Leaves and Melastoma malabathricum L. Leaves on Rats with Diabetic Foot Ulcer", Journal of Applied Sciences, 2019 Publication | 1 % |
| 11 | Abdelsamed I. Elshamy, Naglaa M. Ammar, Heba A. Hassan, Walaa A. El-Kashak et al. "Topical Wound Healing Activity of Myricetin Isolated from Tecomaria capensis v. aurea", Molecules, 2020 Publication | 1 % |

| | | |
|----|---|------|
| 12 | "Bioactive Molecules in Food", Springer Science and Business Media LLC, 2019 Publication | 1 % |
| 13 | www.freepatentsonline.com Internet Source | 1 % |
| 14 | link.springer.com Internet Source | <1 % |
| 15 | www.losingsomeweight.info Internet Source | <1 % |
| 16 | core.ac.uk Internet Source | <1 % |
| 17 | www.ncbi.nlm.nih.gov Internet Source | <1 % |
| 18 | Reem Ashraf Elnahas, Bassma Hassan Elwakil, Salma Sameh Elshewemi, Zakia Ahmed Olama. "Egyptian Olea europaea leaves bioactive extract: Antibacterial and wound healing activity in normal and diabetic rats", Journal of Traditional and Complementary Medicine, 2021 Publication | <1 % |
| 19 | ebin.pub Internet Source | <1 % |
| 20 | www.medsci.org Internet Source | <1 % |

| | | |
|----|---|------|
| 21 | Yuhui Mi, Lei Zhong, Saijian Lu, Po Hu, Yang Pan, Xuelin Ma, Binghui Yan, Zhenhuan Wei, Guangming Yang. "Quercetin promotes cutaneous wound healing in mice through Wnt/ β -catenin signaling pathway", Journal of Ethnopharmacology, 2022 Publication | <1 % |
| 22 | cyberleninka.org Internet Source | <1 % |
| 23 | hdl.handle.net Internet Source | <1 % |
| 24 | investigadores.uandes.cl Internet Source | <1 % |
| 25 | assets.researchsquare.com Internet Source | <1 % |
| 26 | eprints.soton.ac.uk Internet Source | <1 % |
| 27 | qspace.library.queensu.ca Internet Source | <1 % |
| 28 | www.frontiersin.org Internet Source | <1 % |
| 29 | www.oapen.org Internet Source | <1 % |
| 30 | "Plant and Human Health, Volume 3", Springer Science and Business Media LLC, | <1 % |

2019

Publication

31

Wendy A. Mustaqim. "Chapter 166-1
Melastoma malabathricum L.
Melastomataceae", Springer Science and
Business Media LLC, 2020

<1 %

Exclude quotes Off

Exclude matches Off

Exclude bibliography On